



**Journal of
Dentistry and Oral Hygiene**

Volume 8 Number 9, September 2016

ISSN 2141-2472



*Academic
Journals*

ABOUT JDOH

The **Journal of Dentistry and Oral Hygiene (JDOH)** is published monthly (one volume per year) by Academic Journals.

Journal of Dentistry and Oral Hygiene (JDOH) is an open access journal that provides rapid publication (monthly) of articles in all areas of the subject such as endodontics, prosthodontics, Oral Pathology, dento-maxillofacial Radiology, periodontics etc.

The Journal welcomes the submission of manuscripts that meet the general criteria of significance and scientific excellence. Papers will be published shortly after acceptance. All articles published in JDOH are peer-reviewed.

Contact Us

Editorial Office: jdoh@academicjournals.org

Help Desk: helpdesk@academicjournals.org

Website: <http://www.academicjournals.org/journal/JDOH>

Submit manuscript online <http://ms.academicjournals.me/>

Editors

Dr. Denise Evans

*University of Johannesburg
4 Vlei street, Southcrest Alberton, 1449 Gauteng
South Africa.*

Prof. Azza A El-Housseiny

*Faculty of Dentistry, Alexandria university
1 Shamplion St, Massarita, Alexandria.
Egypt .*

Dr. Fawad Javed

*Karolinska Institutet
Box 4064, SE 14104 Huddinge. Stockholm.
Sweden*

Dr. Muneer Gohar Babar

*International Medical University
No. 126, Jalan 19/15B, Bukit Jalil, 57000 Kuala
Lumpur,
Malaysia.*

Dr. Janine Owens

*University of Sheffield, Department of Oral Health
and Development
Claremont Crescent, Sheffield S10 2TU
United Kingdom*

Dr. Satyabodh S.Guttal

*SDM College of Dental Sciences and Hospital
Sattur, Dharwad
India .*

Prof. E.J. Sauvetre

*Université Libre de Bruxelles (Faculty of Medicine)
10 rue bavastro 06300 Nice France
France.*

Dr. Olfat Shaker

*Faculty of Medicine Cairo University
Department of Medical Biochemistry,
Egypt .*

Prof. Ayyaz Ali Khan

*Riphah International University
IIDC&H, Off 7th Ave., G-7/4, Islamabad,
Pakistan.*

Dr. Pei-Yi Chu

*Diagnostic and research pathologist,
Department of Surgical Pathology,
Changhua Christian Hospital/
135 Nan-Shiao Street, Changhua 500-06,
Taiwan.*

Dr. Abeer Gawish

*Al-Azhar University Faculty Of Dental Medicine
4 elsheikh Makhlof Street. Misr Elgedida, Cairo
Egypt.*

Dr. Murali Srinivasan

*Jebel Ali Hospital
PO Box 49207, Dubai,
UAE .*

Dr. Scardina Giuseppe Alessandro

*University of Palermo Department of Oral Sciences
"G. Messina"
Via del Vespro, 129 90127 Palermo
Italy.*

Prof. Hussam M. Abdel-Kader

*Faculty of Dental Medicine, AlAzhar University, Cairo,
Egypt Madent Nasr 11884, Cairo,
Egypt.*

Dr. Mahmoud K. ALiri,

*BD-OmS, PhD, FDS RCS (England),
Jordanian Board, DCE (Ireland).
Associate Professor and Consultant
Faculty of Dentistry, The University of Jordan,
P.O. Box 710193, Amman 11171,
Jordan .*

Dr. Imtiaz Wani

*S.M.H.S Hospital
Srinagar, Kashmir,
India.*

Editorial Board

Dr. Santhosh Kumar

*Darshan Dental College and Hospital
Udaipur,
India .*

Prof. Sharon Struminger

*2350 Broadhollow Road Farmingdale, NY 11735/
Farmingdale State College of State
University of New York
USA.*

Dr. Saurab Bither

*Christain Dental College
C.M.C, Ludhiana. Punjab.
India.*

Dr. Ramesh Chowdhary

*HKE's S.Nijalingappa Institute of Dental Sciences and
Research
Ring Road, Gulbarga-585104,
India.*

Journal of Dentistry and Oral Hygiene

Table of Content: Volume 8 Number 9 September 2016

ARTICLE

- Paediatric mucoepidermoid carcinoma of palate: Literature review and report of a case** 54
Nelly Ruth Limón Garcia, Cesar Villalpando Trejo, Armando Cervantes Alanís and María de la Luz Garza de la Garza
- Periodontal conditions in orthodontic patients using direct and indirect bracket bonding techniques: A randomized study** 59
Maurício Matté Zanini, Carlos Augusto Nassar, Patricia Oehlmeyer Nassar, Priscilla do Monte Ribeiro Busato, Jamille Favarão and Mauro Carlos Agner Busato

Full Length Research Paper

Paediatric mucoepidermoid carcinoma of palate: Literature review and report of a case

Nelly Ruth Limón García¹, Cesar Villalpando Trejo^{1*}, Armando Cervantes Alanís¹ and María de la Luz Garza de la Garza²

¹Departament of Oral and Maxillofacial Surgery, Facultad de Odontología, Universidad Autónoma de Nuevo León, Resident, México.

²Departament of Oral and Maxillofacial Pathology, Facultad de Odontología, Universidad Autónoma de Nuevo León, México.

Received 4 August, 2016; Accepted 30 August, 2016

Mucoepidermoid Carcinoma (MEC) is the most common malignant tumor in salivary glands. About 70% of these tumors are found in the parotid gland, 15 to 20% in the oral cavity, mostly in the palate, and 6 to 10% in the submandibular gland. MEC has female predilection and the mean age at onset is in the 5th decade of life. The treatment decision depends on the histopathology (Low-grade, Intermediate-grade, High-grade). A 12 year-old male with a right palatal tumor, having no association with vital teeth arrived at our service centre. The excisional biopsy reported was: MEC Intermediate-grade. Because few cases of MEC in Paediatric patients have been reported, a review of the literature, with range of age 0-17 years, was made, 24 patients with diagnosis of MEC in Palate, included our case, were found, the average age was 14 (29%), the predilection in genre was female with 19 cases (79%), and 5 cases in Male (21%). MEC has a female predilection and is uncommon in the first decade of life but should be considered even in paediatric patients. The prognosis depends on the clinical stage, grade of the tumor, location, and adequacy of treatment. The presence of nodal disease and distant metastases implies a poor prognosis.

Key words: Mucoepidermoid carcinoma, palate, childhood.

INTRODUCTION

Mucoepidermoid carcinoma (MEC) is the most common malignant salivary gland tumor, statistical data indicate that it is the most common parotid malignancy (89%) and that is the most common malignant salivary gland tumor in children. About 70% of MEC are found in parotid gland,

15-20% in oral cavity, mostly in the palate, and 6 to 10% in submandibular gland. MEC has female predilection 3:1 at fifth decade of life (Marx and Stern, 2012). MEC was originally described by Volkmann in 1895 (Bhat et al., 2014), the oral cancer foundation refers that MEC was

*Corresponding author. E-mail: cesarvi@att.net.mx. Tel: 045-8183629904.

described by Masson and Berger in 1924 and in 1945 Stewart recognized MEC of salivary glands as a separate entity among salivary neoplasm (Ranganath et al, 2011).

Treatment decisions are based on histologic grading. The grading of MEC depends on the mix of cell types. Low grade is characterized by well-form cyst that contains mucin, lined by a mixture of mucos, intermediate and epidermoid cells. Intermediate grade contains smaller and fewer cyst and have more solid appearance, consist of intermediate cells, epidermoid cells, and some mucous cells.

High grade are solid and consist of intermediate and epidermoid cells, which show considerable atypia and mitotic activity is present (Marx and Stern, 2012). A review of literature about MEC of Palate revealed 24 documented cases in paediatric patients, included a case reported by our service of Oral and Maxillofacial Surgery at School of Dentistry of Universidad Autónoma de Nuevo León, México.

Case presentation

A Twelve-years-old Male arrived to our service; a complete anamnesis was made, the patient does not have antecedents or family cancer history, the only relevant antecedent was previous dental injury in anterior- inferior teeth 6 years before. He refers began with a mass in Right Palate five months previous (May, 2015), which was detected by his dentist, biopsy by puncture was practice that time without specific diagnosis.

At clinical examination was made, with oval face, esqueletal class III, absense of inferior anterior theet, tongue and the rest of tissue had normal characteristics, a mass in the right hard palate, 2 cm in size was observed, with blue/red color, diffuse borders, fluctuant, and sesil base, the cervical palpation does not reveal lymph nodes (Figure 1). A Cone Beam was taken, without any bone involvement. An Incisional Biopsy was made (October, 2015), because the characteristics of clinical presentation, it was made superficial and the histopathology report us normal tissue. It was decided to excisional biopsy with a scalpel No. 15, removing the entire lesion 0.5 mm around, hemostasis was made with electrocautery, and an obturator for the defect of tissue was used.

The histopathologic analysis, made with hematoxylyne-and-eosin by the Pathology Department, reported presence of quistic sppaces covered by epidermoid cells and mucus secreting cells. Filling these spaces are nests and diffuse layers of these same cells between a fibrous connective tissue, which correspond to MEC of intermediate grade (Figure 2). The patient actually, 9 months after, has no evidence of lesion; a new Cone beam was taken, with no evidence of bone involvement. An oncological review was conducted by the specialist

with no evidence of tumor.

RESULTS

The literature review include search in Pub Med, JOMS and IJOMS, the range of age was 0 to 17 years, 24 patients with diagnosis of MEC in Palate, including our case, were found. The youngest age was 5 years; 1 case (4%), the oldest 17 years old; 3 cases (13%), the average of age was 14 (29%). The predilection of genre was female with 19 cases (79%), and 5 cases in Male (21%) (Table 1). The most common location was hard palate; 17 cases (71%), followed by junction of hard and soft palate; 4 cases (17%), and 3 cases of soft palate (12%). The time of evolution was not specified in almost all the cases, but 1 year (9%) and 1 month (9%) was the most common. The size was not specified in almost all the cases 13 (54%) and 3 patients reported 2 cm (13%) (Table 1). One case reported bone involvement and another reported erosion of bone. Concerning the Histologic grade: low grade was the most prevalent with 22 cases (92%) of the total, 1 intermediate (4%) and 1 was not specified (4%). The common treatment was excision. One case had recurrence on 5 years follow up (Table 1).

DISCUSSION

The firm attachment of the mucosa of hard palate to the underlying periosteum, the anatomic proximity of the mucosa to the bone, and the abundance of minor salivary glands make the hard palate a unique anatomic region. Within this context, neoplastic lesions of the hard palate may show different characteristics and different histopathologic compositions compared with other anatomic regions. (Aydil et al., 2014). MEC is actually an uncommon tumor in minor glands in child. About 1% - 5% of all salivary glands tumors develop in children and adolescents, and the MEC are the most common malignancy. (Ritwik et al., 2012). In 1987 only 17 cases of MEC of the palate in children had been published. (Gustafsson et al., 1987). Although this salivary gland tumor represents a rare oral lesión in children, it should be considered when a lesion has a similar appearance as a mucocele but is found at a site other than the lower labial mucosa. (Flaitz, 2000). The mucocele is a common, reactive lesion of salivary glands that is seen frequently in children. This lesion presents as a dome shaped, translucent blue swelling that is fluid-filled. (Flaitz, 2000). Few series of cases describing salivary gland tumors in the pediatric population have been published. This Case represent an additional case of a Intermediate-grade MEC of the palate of a 12 years old child. Here, the average of age was 14 (29%), the predilection of genre was female with 19 cases (79%),

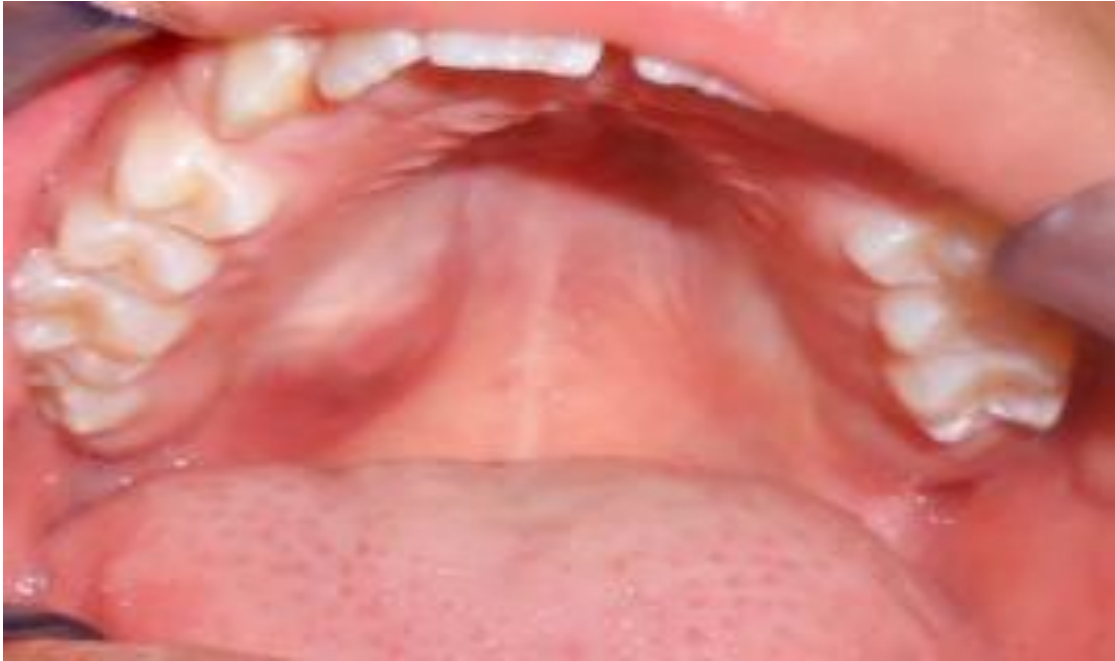

Figure 1. Initial clinical presentation

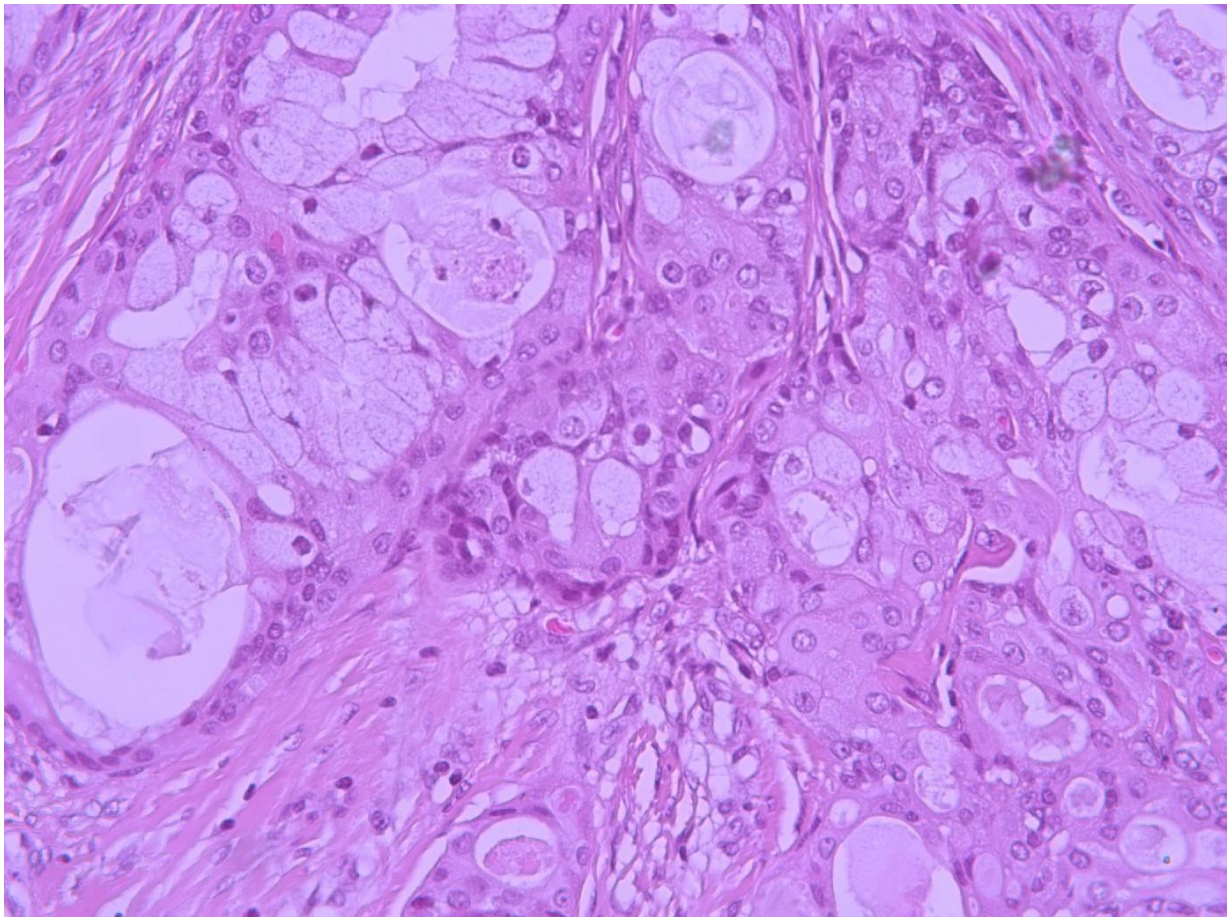


Figure 2. Photomicrograph of hematoxylin-and-eosin section of MEC. 40X Magnification.

Table 1. Paediatric MEC reported at palate.

S/N	References	Case reported at the reference	Age	Genere	Site	Duration	Size	Bone involvement	Histological grade	Treatment	Recurrence	Follow-Up
1	Budnick (1982)	1	12	Female	Hard Palate	NS	2	NS	Low	Excision down to bone	No	3 years
2	Gustafsson et al (1987)	1	13	Female	Hard Palate	2 Months	1.5	NS	Low	Resección	No	1.5 years
3	Fonseca et al. (1991)	2	14	Male	Soft Palate	NS	NS	NO	Low	Two surgery	Yes/5 years	NS
4	Fonseca et al. (1991)	2	14	Female	Soft Palate	NS	NS	NO	Low	surgey	no	6 Months
5	April et al. (1997)	1	10	Female	Junction Hard/soft Palate	1 month	0.5	NO	Intermediate	NS	NS	NS
6	Aguilar et al. (1998)	1	13	Female	Junction Hard/soft Palate	7 months	3	NO	NS	Excision	NS	NS
7	Flaitz (2000)	1	8	Male	Hard Palate	9 monts	2	NO	Low	Wide local excision down to periosteum	NS	NS
8	Caccamese and Ord (2002)	23	17	Male	Junction Hard/soft Palate	NS	1.5	NO	Low	Local Resection	No	94 months
9	Caccamese and Ord (2002)	23	14	Female	Hard Palate	1 month	1	NS	Low	Excision	No	62 months
10	Caccamese and Ord (2002)	23	16	Female	Palate	1 year	2.5	NO	Low	Local Resection	No	42 months
11	Morales et al (2007)	1	14	Female	Hard Palate	1 year	5	NO	Low	Transoral resection	No	4 years
12	Pérez et al. (2008)	9	6	Female	Hard Palate	2 monts	NS	NS	Low	Local Excision	NS	NS
13	Pérez et al. (2008)	9	12	Female	Hard Palate	1 month	NS	NS	Low	Local Excision	NS	NS
14	Pérez et al. (2008)	9	14	Female	Hard Palate	4 months	NS	NS	Low	Local Excision	NS	NS
15	Pérez et al. (2008)	9	16	Male	Hard Palate	2 months	NS	NS	Low	Local Excision	NS	NS
16	Pérez et al. (2008)	9	17	Female	Hard Palate	2 months	NS	NS	Low	Local Excision	NS	NS
17	Pérez et al. (2008)	9	17	Female	Soft Palate	36 months	NS	NS	Low	Local Excision	NS	NS
18	Ávila et al. (2011)	13	16	Female	Palate	NS	NS	NS	Low	NS	NS	NS
19	Ritwik et al. (2012)	15	15	Female	Hard Palate	3 weeks	NS	NO	Low	Excision	No	21 years
20	Ritwik et al. (2012)	15	15	Female	Hard Palate	NS	3	NS	Low	Excision	No	19 years
21	Ritwik et al. (2012)	15	14	Female	Hard Palate	NS	NS	NS	Low	NS	No	9 years
22	Sengul et al.(2013)	15	12	Female	Hard Palate	2 years	8 mm	Yes	Low	Excision	NS	3 years
23	Baumgardt et al (2014)	1	5	Female	Hard Palate	1 week	2.5	No	Low	Resection long the adjacent bone	NS	NS
24	This Case	1	12	Male	Junction Hard/soft Palate	5 months	2	No	Low	Excision	No	9 months

*NS: Not Specified.

the histopathological grade of prevalence was low grade, with 22 cases (92%). Fluctuance and a light blue color are helpful diagnostic clinical clues. MEC must be considered in the differential diagnosis of a lump or mass in a salivary gland-bearing area, especially the palate (Ritwik et al., 2012). Mucoepidermoid carcinoma requires surgical excision. Low-grade lesions may be treated with wide local re-section.

High-grade neoplasms often require treatment of the cervical lymph nodes by a selective neck dissection, radiation, or both (Ritwik et al., 2012).

Conflict of Interests

The authors have not declared any conflict of interests.

REFERENCES

- Aguilar MC, Dayrell CQ, Mesquita RA (1998). Palatal mucoepidermoid carcinoma in a child. *J. Clin. Pediatr. Dent.* 22:347-349.
- April MM, Brodsky LS, Cunningham MJ, Harari PM, Harrison L, Poje CP (1997). Mucoepidermoid carcinoma in a 10-year-old girl. *Head Neck* 19:431-435.
- Ávila R, Samar M, Fonseca I, Olmedo L, Asís O, Ferraris R (2011). Carcinoma Mucoepidermoide de Glándulas Salivales: Factores Pronósticos Histológicos e

- Inmunohistoquímicos. *Int. J. Morphol.* 29(2):455-462.
- Aydil U, Kızıl Y, Kadri F, Köybaşıoğlu A, Uslu S (2014). Neoplasms of the Hard Palate. *J. Oral. Maxillofac. Surg.* 72:619-626.
- Baumgardt C, Günther L, Sari-Rieger A, Rustemeyer J (2014). Mucoepidermoid carcinoma of the palate in a 5-years-old-girl: case report and literatura review. *Oral Maxillofac. Surg.* 18:465-469.
- Bhat K, Pandey B, Shetty P, Manohar V, Shruthilaxmi MK, Patidar M (2014). Sclerosing Mucoepidermoid Carcinoma: A unique case. *Sultan Qaboos University Med. J.* 14(2):e249.
- Budnick SD (1982). Minor-salivary-gland tumors in children. *ASDC J. Dent. Child.* 49(1):44.
- Caccamese JF, Ord RA (2002). Paediatric mucoepidermoid carcinoma of the palate. *Int. J. Oral Maxillofac. Surg.* 31:136-139.
- Flaitz CM (2000). Mucoepidermoid carcinoma of the palate in a child. *Pediatr. Dent.* 22:292-293.
- Fonseca I, Martins AG, Soares J (1991). Epithelial salivary gland tumors of children and adolescents in southern Portugal: a clinicopathologic study of twenty-four cases. *Oral Surg. Oral Med. Oral Pathol.* 72:696-701.
- Gustafsson H, Dahlqvist A, Anniko M, Carlsoo B (1987). Mucoepidermoid carcinoma in a minor salivary gland in childhood. *J. Laryngol. Otol.* 101:1320-1323.
- Marx RE, Stern D (2012). *Oral and maxillofacial pathology.* Chicago: Quintessence. 2003.
- Morales P, Pereira C, Almeida O, Perez D, Correa ME, Alves F (2007). Paediatric intraoral mucoepidermoid carcinoma mimicking a bone lesion. *Int. J. Pediatr. Dent.* 17:151-154.
- Pérez DE, Pires FR, Alves F, López M, Almeida O, Kowalski L (2008). Juvenile Intraoral Mucoepidermoid Carcinoma. *J. Oral Maxillofac. Surg.* 66:308-311.
- Ranganath MK, Matmari V, Narayanaswamy UD, Bavle RM (2011). Mucoepidermoid carcinoma presenting as a retromolar mucocele. *Ann. Maxillofac. Surg.* 1(1):66.
- Ritwik P, Cordell K, Brannon R (2012). Minor salivary gland mucoepidermoid carcinoma in children and adolescents: a case series and review of the literatura. *J. Med. Case Rep.* 6:182
- Sengul F, Simsek S, Cakur B (2013). Mucoepidermoid Carcinoma in a Minor Salivary Gland in a Child. *Case Rep. Dent.* 2013.

Full Length Research Paper

Periodontal conditions in orthodontic patients using direct and indirect bracket bonding techniques: A randomized study

Maurício Matté Zanini^{1*}, Carlos Augusto Nassar², Patricia Oehlmeyer Nassar², Priscilla do Monte Ribeiro Busato³, Jamilye Favarão¹ and Mauro Carlos Agner Busato²

¹Area of Dental Materials, Piracicaba Dental School, State University of Campinas, Piracicaba, São Paulo, Brasil.

²Stricto Sensu Post-graduation Dental Program, State University of West Paraná, Cascavel, Paraná, Brasil.

³Dentistry, Dental School, State University of West Parana, Cascavel, Parana, Brasil.

Received 19 August, 2015; Accepted 18 March, 2016

The aim of this study was comparing two orthodontic bracket bonding techniques (direct and indirect), with regard to the following variables: plaque index; gingival index, evaluation of gingival crevicular fluid, and white spots on tooth enamel. Seventeen patients were randomly selected (10 men and 7 women) with a mean age of 15.8 years, and these were subjected to comprehensive orthodontic treatment (braces), totaling a sample size of 260 teeth examined. The experimental model used was the split-mouth technique, in each patient, the maxillary brackets in one hemi-arch were bonded by the direct, and in the other by the indirect technique, the same occurring in the mandibular arch. Assessments were performed in the following time intervals: pre-bonding, one, three and six months after initial placement of the brackets. The data were subjected to statistical analysis by the Kruskal-Wallis test (Dunn's post-test) to assess the intra-group evolution of the variables. The Wilcoxon test was used for comparison between groups. The brackets bonded to teeth by the direct technique showed a higher number of surfaces with the presence of bacterial plaque and bleeding, when compared with the indirect technique, in time intervals of 3 and 6 months. For measurement of fluid, direct bonding showed increased index in 3-month evaluation. The occurrence of white spots showed no statistical difference between groups. As conclusion, indirect technique shows less oral health impairment with a lower incidence of plaque accumulation, bleeding and fluid.

Key words: Orthodontics, indirect bonding, periodontics, gingivitis, dental caries.

INTRODUCTION

The bracket bonding technique conventionally used by orthodontists is the direct type, in which the bracket is

placed directly on the tooth. However, this technique has some disadvantages, such as performing it in areas of

*Corresponding author. E-mail: mauriciomattezanini@gmail.com.

difficult access in the mouth, such as the region of posterior teeth out of the correct position in the arch, the tiredness and stress of both the orthodontist and patient, leading to incorrect bracket bonding in patients, and unsuccessful final positioning of the teeth (Ciuffolo, Tenisci and Pollutri, 2012; Nichols; Gardner and Carballeyra, 2013).

With the aim of overcoming these disadvantages, indirect bonding appeared. In this technique, the brackets are positioned on the patient's plaster casts, using resin composite, and by means of a pre-formed tray, the brackets are transferred to the patient's teeth (Ciuffolo et al., 2012; Silverman et al., 1972). In indirect bonding, the precision of bracket position may be more easily obtained by the multidimensional visualization of the teeth, which in turn contributes the accuracy in the final positioning of the teeth (Bozelli et al., 2013; Castilla et al., 2014; Mizrahi, 1982). When correctly performed, the indirect technique leads to reduction in stress of the patient and professional at the time of placing the appliance, by diminishing the chair-time (Bozelli et al., 2013; Castilla et al., 2014; Ciuffolo, Tenisci and Pollutri, 2012; Deahl et al., 2007; Gange, 2000).

However, as yet there are few orthodontists who routinely use indirect bonding, because there are persistent doubts about the consistency and predictability of the brackets bonding to the teeth, cost of material (Gayake et al., 2013), and precision in positioning the brackets (Castilla et al., 2014; Koo, Chung and Vanarsdall, 1999). Another factor pointed out as being controversial is the excessive amount of adhesive material left around the brackets with the use of the indirect bonding technique (Gayake et al., 2013; Kanashiro et al., 2014).

In general, fixed appliance prevent the maintenance of good oral hygiene, particularly when brackets are bonded with excessive adhesive material, thus favoring bacterial plaque accumulation (Al-Anezi and Harradine, 2012; Jordan and LeBlanc, 2002; Nassar et al., 2009), which in turn could lead to the occurrence of gingival inflammation (Al-Anezi and Harradine, 2012; Miles, 2010) and enamel demineralization - white spots (O'Reilly et al., 2013; Tufekci et al., 2011). If on the one hand, indirect bonding allows the removal of excess resin during the act of laboratory bonding; on the other hand, it does not allow the predictability of adhesive flow during its clinical stage (Ciuffolo et al., 2012; Kanashiro et al., 2014; Miles, 2010; Mohode, 2012).

By virtue of the orthodontic bracket tending to be an accessory that retains plaque (Al-Anezi and Harradine, 2012; Jordan and LeBlanc, 2002; Nassar et al., 2009), and knowing that indirect technique is a procedure increasingly being used by orthodontists (Ciuffolo et al., 2012; Gange, 2000; Silverman et al., 1972). The aim of this research was to compare the plaque index, gingival index, evaluate the gingival crevicular fluid and index of white spots on tooth enamel in patients submitted to

bracket bonding by means of the direct and indirect techniques.

MATERIALS AND METHODS

This was a prospective, randomized study, conducted between August 2013 and October 2014. Before conducting it, the study was approved by the Ethics Committee on Research in Human Beings of the State University of West Paraná, under report No.16610513.5.0000.0107. The criteria for inclusion in the research were: the need for treatment with a fixed appliance, and symmetrical malocclusion when evaluated in the sagittal direction. The exclusion criteria were: very severe crowding, abnormality in the morphology of dental crowns, caries, and extensive restorations. For the research, 17 patients were randomly selected (10 men and 7 women, with a mean age of 15.8 years) from among those who requested standard orthodontic documentation for the confirmation of clinical diagnosis and preparation of planning, totaling a sample number of 248 teeth for the research, according to Flowchart 1.

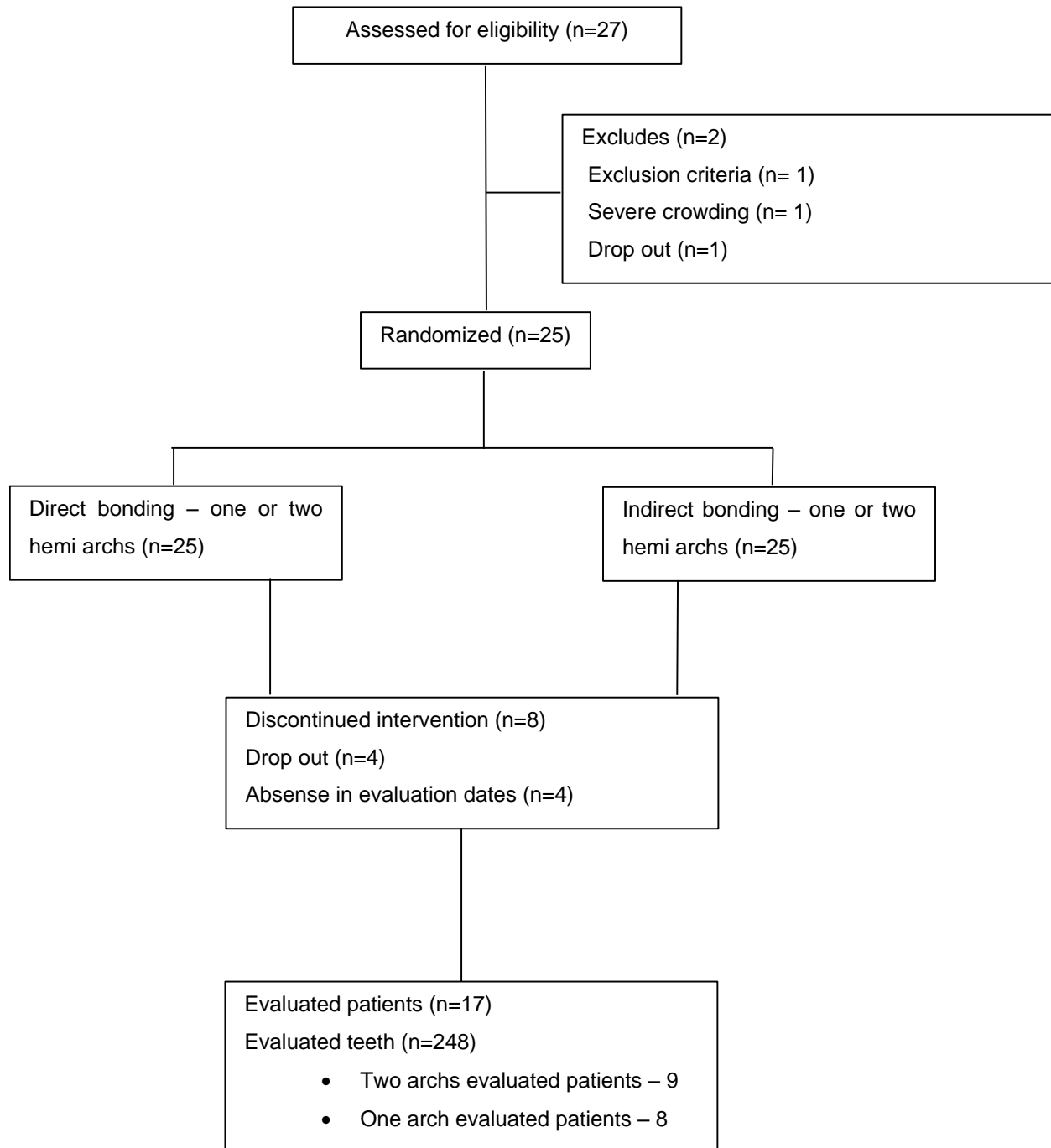
Assembly of the orthodontic appliance of these patients occurred in accordance with the split-mouth model, in which metal orthodontic brackets, of the Roth prescription (Morelli – Sorocaba – SP – Brazil), were bonded to the maxillary right and mandibular left hemiarches by means of the direct technique; and bonded to the maxillary left and mandibular right hemiarches, by the indirect technique (Nassar et al., 2013). This protocol explains the manner in which this research was considered randomized, since each patient had brackets bonded by means of the two techniques. All the patients were instructed regarding the mechanic control (modified Bass technique plus dental floss). The same operator performed the laboratory stage of indirect bonding, and the clinical stages of direct and indirect bonding, according to Table 1. All the evaluations were performed by the same, previously calibrated operator, as follows:

Plaque index and gingival index

A clinical exam of each patient was performed before bonding, and in the return visits at one, three and six months, in order to observe: a) Plaque index of Silness and Loe, by the presence or absence of bacterial plaque on the vestibular, palatine, mesial and distal surfaces of the incisors, canines and premolars, with designation of codes 0 for absence or 1 for presence of visible plaque (Silness and Loe, 1964) and b) Gingival index of Loe and Silness, in which the gingival inflammatory condition was evaluated by the presence or absence of bleeding in vestibular and palatine sulcus (Loe and Silness, 1963), by means of probing with a millimeter probe (Williams #23). After this, the percentages of surfaces with the presence of bacterial plaque and bleeding were calculated. Using these data, the relationship of difference in resin remainders on the direct and indirect bonding with the presence of plaque and gingival index was evaluated.

Gingival crevicular fluid

Before bonding, and at one, three and six months after the insertion of the appliance, gingival crevicular fluid was collected from the vestibular sulcus of the central incisors, canines and second premolars of each of the patients in the study for the evaluation of gingivitis. This collection was made by introducing a small absorbent paper cone into each sulcus, and evaluating it for thirty seconds (Hinrichs et al., 1984).



Flowchart 1. Evaluated patients.

After the removal of each cone, they were inserted in a solution with 99ml of absolute alcohol (ethanol) and 1 g of ninyhydrin (2,2-dihydroxy-hydrydin-1,3-dione) marker for 2 min. This substance is generally used for the detection of primary amines, particularly of amino acids, because when they react with these free amines, a dark blue or purple color, known as Ruhemann purple, is produced (Hinrichs et al., 1984). After being marked and dried, the cones were photographed by the same researcher, in accordance with the following standards: resolution – all the images were obtained with

a Canon EOS T3i (Canon Inc. – Taiwan) camera, with a circular flash in automatic mode, opening at 32, opening speed at 1/60 and ISO 100; focus – all the photographs were taken with focus 1-1.02-0.31 mm, against a black background; distance – seeing that all the cones were photographed with the same focus, the distance required between the camera and cone in order to obtain clarity, was always the same. The gingival crevicular fluid collection area in the photographic image was measured by means of the program *ImageTool* (San Antonio, Texas, USA). To calibrate the program, it

Table 1. Direct and indirect bonding (step by step).

Laboratory stage - Indirect bonding	Clinical stage – a) Direct b) Indirect bonding
1. patient's model - alginate Cavex Color Change (Cavex Holland BV – Haarlem – Holland) and stone plaster Herodent (Coltene SA – Bonsucesso – RJ – Brazil)	1. prophylaxis with extra fine pumice stone (SS White – Rio de Janeiro – RJ – Brazil), washing and drying
2. vestibular surfaces isolation of teeth on the plaster casts with a sealant for acrylic resin Cel Lac (SS White – Rio de Janeiro – RJ – Brazil)	2. 37% phosphoric acid Condac (FGM– Joinville – SC – Brazil) application for 30 seconds, water application for 10 seconds and drying for 10 seconds on each tooth
3. positioning each bracket on the plaster casts (according the the orthodontic treatment of each patient) with resin Transbond XT (3M Unitek – Monrovia – California – USA), at the bases of the parts	3.a) adhesive Transbond XT (3M Unitek – Monrovia – California – USA) application and light polymerization for 20 seconds on each tooth 3.b) chemical activation adhesive Concise (3M Unitek – Monrovia – California – USA) application on teeth and brackets bases, for 3 seconds on each
4. light polymerization of each bracket for 20 seconds from the cervical and 20 seconds from the occlusal side. For this purpose, the same light polymerizing appliance Dabi Atlante Ultralux (Dabi Atlante – Ribeirão Preto – SP – Brazil) was used, previously calibrated with irradiance of 550mw/cm ² , for direct bonding as well	4.a) brackets positioning on the teeth (according to the orthodontic treatment of each patient), with resin from the Transbond XT kit, at the bases of the brackets, and excess resin removal 4.b) positioning of the tray on the patient's teeth and waiting for 5 minutes
5. patient's tray - condensation silicone Perfil (Coltene SA – Bonsucesso – RJ – Brazil) and its placement on the teeth in the model	5.a) light polymerization of each bracket for 20 seconds from the cervical and 20 seconds from the occlusal side 5.b) removal of the silicone tray using a scalpel blade
6. removal of excess silicone using a scalpel blade and detachment of the tray from the model, with the brackets adhered to it	
7. airborne abrasion with 90 µm aluminum oxide particles (Bio Art Ltda – São Carlos – SP – Brazil) at each bracket base, for one second, to remove sealant excess	

was necessary to place a ruler on the cones in the photos to make marks in millimeters, and after this the area marked on each cone was measured with the software in mm² (Figure 1).

White spot index

In the same clinical exams mentioned above, the presence of white spots on the enamel of the vestibular and palatine surfaces of those teeth was verified. The sites examined were classified as presence or absence of white spots; the percentage value of surfaces with the presence of white spots was calculated in order to compare the two techniques (O'Reilly et al., 2013; Tufekci et al., 2011).

Statistical analysis

After six months of obtaining information from the sample units of indirect bonding and those of direct bonding, the data were evaluated by the statistical method, using the program *Biostat 5.0* (Instituto Mamirauá – Belém – Pará - Brazil). The data obtained were submitted to statistical analysis: the Kruskal-Wallis (Dunn post-test) to evaluate the intra-group evolution of the variables. The Wilcoxon test was used for inter-group comparisons. To evaluate the reliability of the measurements obtained with reference to inflammatory fluid, after one month, new measurement of the images were made, in order to measure the method error (systematic - paired *t*-test and casual - Dahlberg formula).

RESULTS

The mean method error, either systematic or casual, showed there was no statistically significant difference between the measurements obtained for the area of the cones in the quantitative evaluation of crevicular fluid ($p>0.05$).

Table 2 shows the percentages of the plaque index for direct and indirect bonding. In the direct bonding group, there was a significant increase in plaque index, showing a remarkable difference between the time intervals before bonding and the periods of 3 and 6 months ($p<0.01$). Whereas, in the indirect bonding group, there was no statistically significant variation in the plaque index ($p>0.05$). For the inter-group comparisons a larger number of faces with presence of bacterial plaque was detected for the direct bonding groups in the periods of 3 months ($p<0.05$) and 6 months ($p<0.01$).

Table 3 shows the percentages of the gingival index for direct and indirect bonding. In the direct bonding group, there was a significant increase, showing a remarkable difference between the time intervals before bonding and the periods of 3 and 6 months ($p<0.01$). Whereas, in the indirect bonding group, there was no statistically



Figure 1. Gingival crevicular fluid collection area in the photographic image.

Table 2. Plaque index values (average \pm standard deviation). Results expressed as percentage.

Bonding type	Before bonding	30 days	90 days	180 days
Direct bonding	54.99* (23.64)	72.09##* (20.35)	80.44# (21.42)	88.30# (17.24)
Indirect bonding	58.00* (25.08)	66.10* (27.05)	69.92* (26.50)	74.41* (30.29)

* Different symbols (*,#) indicate intra-group statistically significant difference over time, as well as, in inter-group comparison by evaluation time ($p < 0.05$). At least an equal symbol indicates statistical similarity ($p < 0.05$).

Table 3. Gingival index values (average \pm standard deviation). Results expressed as percentage.

Bonding type	Before bonding	30 days	90 days	180 days
Direct bonding	11.92* (12.26)	20.62##* (16.04)	26.20# (19.30)	35.80# (24.73)
Indirect bonding	14.85* (15.81)	17.18* (17.89)	17.47* (19.01)	21.97* (20.52)

* Different symbols (*,#) indicate intra-group statistically significant difference over time, as well as, in inter-group comparison by evaluation time ($p < 0.05$). At least an equal symbol indicates statistical similarity ($p < 0.05$).

significant variation in the gingival index ($p > 0.05$). For the inter-group comparisons a larger number of surfaces with presence of bleeding were detected for the direct bonding groups in the periods of 3 months ($p < 0.05$) and 6 months ($p < 0.01$).

Table 4 shows the data for the areas of the cones (inflammation - gingival crevicular fluid) for the direct and indirect bonding groups. In the direct bonding group there was a significant increase in inflammation between the first and second evaluations, and this remained stable until the last exam ($p < 0.01$). Whereas, in the indirect bonding group, there was no statistically significant variation in inflammation ($p > 0.05$). For the inter-group comparisons a higher level of inflammation was detected for the direct bonding groups in the period of 3 months ($p < 0.01$).

Table 5 shows the percentages of the occurrence of

white spots for direct and indirect bonding. In the groups evaluated there was no significant increase in white spots over time ($p > 0.05$). For the inter-group comparison no significant differences were detected between the techniques for white spots in the periods evaluated ($p > 0.05$).

DISCUSSION

Although the indirect bonding technique was recommended in the 1970s (Silverman et al., 1972), the topic has sometimes been discussed again in the world literature (Bozelli et al., 2013; Castilla et al., 2014; Ciuffolo et al., 2012; Deahl et al., 2007; Gange, 2000; Gayake et al., 2013; Hodge et al., 2014; Kanashiro et al., 2014; Koo et al., 1999; Miles, 2010; Mohode, 2012;

Table 4. Gingival fluid demarcation area values (average \pm standard deviation). Results expressed in mm².

Bonding type	Before bonding	30 days	90 days	180 days
Direct bonding	1.57* (0.90)	1.99# (0.90)	1.92# (0.88)	1.79# (0.89)
Indirect bonding	1.57* (0.87)	1.88* (0.97)	1.55* (0.63)	1.77* (0.74)

* Different symbols (*,#,\$) indicate intra-group statistically significant difference over time, as well as, in inter-group comparison by evaluation time ($p < 0.05$). At least an equal symbol indicates statistical similarity ($p < 0.05$).

Table 5. White spots index (average \pm standard deviation). Results expressed as percentage.

Bonding type	Before bonding	30 days	90 days	180 days
Direct bonding	6.78* (7.60)	7.90* (7.76)	11.93* (12.90)	9.65* (9.44)
Indirect bonding	9.90* (9.99)	14.33* (15.62)	17.01* (16.44)	14.14* (14.82)

Different symbols (,#) indicate intra-group statistically significant difference over time, as well as, in inter-group comparison by evaluation time ($p < 0.05$). At least an equal symbol indicates statistical similarity ($p < 0.05$).

Nichols et al., 2013). At present, it is routinely used in the lingual technique, and eventually in the technique for brackets bonded from the vestibular side, when the professional has the intention to hasten the clinical act of positioning the brackets, thereby reducing chair-time, with this factor being an aspect on which there is unanimity in the studies (Bozelli et al., 2013; Castilla et al., 2014; Ciuffolo et al., 2012).

However, a relevant variable to be considered during orthodontic treatment is the maintenance of periodontal health, since the orthodontic bracket tends to be an accessory that retains bacterial plaque (Al-Anezi and Harradine, 2012; Jordan and LeBlanc, 2002; Nassar et al., 2009). The doubt that motivated this study was precisely whether the type of adhesive - with chemical polymerization - used in the indirect technique, would have more chance of causing deleterious effects on the periodontium. This is because, in this type of technique there is no predictability about the flow of the adhesive in its clinical stage (Ciuffolo et al., 2012; Kanashiro et al., 2014; Miles, 2010; Mohode, 2012), due to the lack of access caused by the transfer tray.

On the other hand, the control of excess resin appears to be better in the indirect technique, since the excess is removed around the brackets on the teeth in the plaster cast - laboratory stage (Ciuffolo et al., 2012), differently from the direct technique, in which the excess is removed from the tooth itself. This is difficult in areas to which access is difficult, and may lead to altering the position of the bracket (Hodge et al., 2004). The scarcity of articles in literature about the periodontal condition with the use of the indirect technique, and about the relationship with the adhesives used in this technique, has resulted in the choice of four aspects evaluated: the plaque index, gingival index, gingival crevicular fluid and the white spot index.

In this study, it was observed that the evolution of the data with regard to bacterial plaque and bleeding

occurred in the same manner (Tables 2 and 3), with a significant increase in direct bonding, showing a remarkable difference between the time interval before bonding and the periods of 3 and 6 months. In the indirect bonding group, there was no statistically significant variation in the two above-mentioned indices. For the inter-group comparisons a larger number of surfaces with presence of bacterial plaque were detected for the direct bonding groups in the periods of 3 and 6 months. The results of increase in difficulty with performing oral hygiene, and consequent high plaque and bleeding indices were expected (Klöhner and Pfeifer, 1974; Steinberg and Eyal, 2004; Zachrisson and Zachrisson, 1972) but the surprising result was the better response of the indirect technique, with regard to these parameters, given that this has not been tested comparatively in the literature.

Although researches commonly use the plaque index and gingival index (Loe and Silness, 1963; Silness and Loe, 1964) for periodontal evaluation in orthodontics, another aspect evaluated in this study was the gingival crevicular fluid. The methodology chosen for this purpose was by marking absorbent paper cones used to collect this fluid as a chemical marker (Hinrichs et al., 1984), which was shown to be efficient, since the results of this requisite also pointed towards the superiority of maintaining good periodontal conditions by means of the indirect bonding technique (Table 4).

Another factor that pointed out the better results of the indirect technique, by means of validation of the evaluations performed, was the split-mouth design of the study, because the periodontal parameters in the initial evaluation were shown to be equal from a statistical point of view. Moreover, starting with the same oral hygiene condition in order to make comparisons about bonding techniques, there was no influence of confounding factors, such as the systemic status of the patient, dexterity for performing brushing and use of dental floss.

By virtue of the similarity of the results of plaque index, gingival index and gingival crevicular fluid, associated with the good relationship of the indirect technique with plaque control found in the literature (Dalesandri et al., 2012) it would seem just to affirm that the removal of excess resin composite would have more relevance in the maintenance of periodontal health, than the control of eventual excess of adhesive.

This periodontal superiority of the indirect technique did not reflect on the white spot index, which showed no statistical differences between the direct and indirect techniques (Table 5). This raises the hypothesis of its appearance not being related to types of adhesive or the manner in which the accessories were bonded, but rather the fixed orthodontic treatment itself, as has been related in the literature (Mizrahi, 1982; Srivastava et al., 2013; Tufekci et al., 2014). Mizrahi (1982) and Tufekci et al. (2014) determined the prevalence of white spots before and after orthodontic treatment, with the former relating a significant increase of 12.3% in prevalence and 60% for the opacity index (Mizrahi, 1982), and the latter author observed an incidence of 38% for the period of six months, 46% for twelve months, while there was 11% for the control group (Tufekci et al., 2014). Due to the indirect technique better results, its clinical application is valid to minimize the undesirable periodontal effects, since that clinical results are also good.

Conclusions

The indirect technique showed a lower level of compromise of oral health, since both the plaque indices, gingival indices and quantity of gingival crevicular fluid did not alter significantly with the passage of time in this technique, differently from the direct technique. There was no difference between the bonding techniques with regard to the appearance of white spots.

Conflict of interests

The authors have not declared any conflict of interests.

REFERENCES

- Al-Anezi AS, Harradine NW (2012). Quantifying plaque during orthodontic treatment. *Angle Orthod.* 82(4):748-753.
- Bozelli JV, Bigliuzzi R, Barbosa HA, Ortolani CL, Bertoz FA, Faltin Junior K (2013). Comparative study on direct and indirect bracket bonding techniques regarding time length and bracket detachment. *Dental Press J. Orthod.* 18(6):51-57.
- Castilla AE, Crowe JJ, Moses JR, Wang M, Ferracane JL, Covell DA (2014). Measurement and comparison of bracket transfer accuracy of five indirect bonding techniques. *Angle Orthod.* 84(4):607-614.
- Ciuffolo F, Tenisci N, Pollutri L (2012). Modified bonding technique for a standardized and effective indirect bonding procedure. *Am. J. Orthod. Dentofacial Orthop.* 141(4):504-509.
- Dalesandri D, Dalesandri M, Bonetti S, Visconti L, Paganelli C (2012). Effectiveness of na indirect bonding technique in reducing plaque accumulation around braces. *Angle Orthod.* 82(2):313-318.
- Deahl ST, Salome N, Hatch JP, Rugh JD (2007). Practice-based comparison of direct and indirect bonding. *Am J Orthod Dentofacial Orthop* 132(6):738-742.
- Gange P (2000). More on indirect bonding. *Am. J. Orthod. Dentofacial Orthop.* 117(1):18A.
- Gayake PV, Chitko SS, Sutrave N, Gaikwad PM (2013). The direct way of indirect bonding--the combined effect. *Int J Orthod Milwaukee* 24(3):15-17.
- Hinrichs JE, Bandt CL, Smith JÁ, Golub LM (1984). A comparison of 3 systems for quantifying gingival crevicular fluid with respect to linearity and the effects of qualitative differences in fluids. *J. Clin. Periodontol.* 11(10):652-661.
- Hodge TM, Dhoptkar AA, Rock WP, Spary DJ (2004). A randomized clinical trial comparing the accuracy of direct versus indirect bracket placement. *J. Orthod.* 31(2):132-137.
- Jordan C, LeBlanc DJ (2002). Influences of orthodontic appliances on oral populations of mutans streptococci. *Oral Microbiol. Immunol.* 17(2):65-71.
- Kanashiro LK, Robles-Ruiz JJ, Ciamponi AL, Medeiros IS, Dominguez GC, de Fantini SM (2014). Effect of adhesion boosters on indirect bracket bonding. *Angle Orthod.* 84(1):171-176.
- Klöehn JS, Pfeifer JS (1974). The effect of orthodontic treatment on the periodontium. *Angle Orthod.* 44:127-134.
- Koo BC, Chung CH, Vanarsdall RL (1999). Comparison of the accuracy of bracket placement between direct and indirect bonding techniques. *Am. J. Orthod. Dentofacial Orthop.* 116(3):346-351.
- Loe H, Silness J (1963). Periodontal disease in pregnancy - Prevalence and severity. *Acta Odontol. Scand.* 21:533-551.
- Miles P (2010). Indirect bonding--do custom bases need a plastic conditioner? A randomised clinical trial. *Aust. Orthod. J.* 26(2):109-112.
- Mizrahi E (1982). Enamel demineralization following orthodontic treatment. *Am. J. Orthod.* 82:62-67.
- Mohode R (2012). Minimizing adhesive flash during indirect bonding of a lingual retainer. *J. Clin. Orthod.* 46(4):233-234.
- Nassar PO, Bombardelli CG, Walker CS, Neves KV, Tonet K, Nishi RN, Bombonatti R, Nassar CA (2013). Periodontal evaluation of different toothbrushing techniques in patients with fixed orthodontic appliances. *Dental Press J. Orthod.* 18(1):76-80.
- Nichols DA, Gardner G, Carballeyra AD (2013). Reproducibility of bracket positioning in the indirect bonding technique. *Am. J. Orthod. Dentofacial Orthop.* 144(5):770-776.
- O'Reilly MT, De Jesús Viñas J, Hatch JP (2013). Effectiveness of a sealant compared with no sealant in preventing enamel demineralization in patients with fixed orthodontic appliances: a prospective clinical trial. *Am. J. Orthod. Dentofacial Orthop.* 143(6):837-844.
- Silness J, Loe H (1964). Periodontal disease in pregnancy - Correlation between oral hygiene and periodontal condition. *Acta Odontol. Scand.* 22:121-135.
- Silverman E, Cohen M, Gianelly AA, Dietz VS (1972). A universal direct bonding system for both metal and plastic brackets. *Am. J. Orthod.* 62(3):236-244.
- Srivastava K, Tikku T, Khanna R, Sachan K (2013). Risk factors and management of white spot lesions in orthodontics. *J. Orthod. Sci.* 2(2):43-49.
- Steinberg D, Eyal S (2004). Initial biofilm formation of *Streptococcus sobrinus* on various orthodontics appliances. *J. Oral Rehabil* 31(11):1041-1045.
- Tufekci E, Dixon JS, Gunsolley JC, Lindauer SJ (2011). Prevalence of white spot lesions during orthodontic treatment with fixed appliances. *Angle Orthod.* 81(2):206-210.
- Tufekci E, Pennella DR, Mitchell JC, Best AM, Lindauer SJ (2014). Efficacy of a fluoride-releasing orthodontic primer in reducing demineralization around brackets: an in-vivo study. *Am. J. Orthod. Dentofacial Orthop.* 146(2):207-214.
- Zachrisson S, Zachrisson BU (1972). Gingival condition associated with orthodontic treatment. *Angle Orthod.* 42:26-34.



Journal of Dentistry and Oral Hygiene

Related Journals Published by Academic Journals

- *Journal of Medicinal Plant Research*
- *Journal of Parasitology and Vector Biology*
- *Clinical Reviews and Opinions*
- *Journal of AIDS and HIV Research*
- *Journal of Cell Biology and Genetics*
- *Medical Practice and Reviews*

academicJournals